WestVETS

Wound Treatment

Part 2 - Deep Wounds

by Sarah Van Dyk, BVSc (Hons)

Finding your horse with a wound can be a stressful situation but it is one which all horse owners will inevitably find themselves in at some stage.

In the next two articles of this three-part series, Dr Sarah van Dyk from WestVETS discusses deeper wounds.

Deeper wounds are the types of wounds that involve the skin and also underlying tissue including connective tissue, muscle or even bone. They can occur as a result of contact with fencing, pieces of wood, trees, metal, floats and many other objects.

In this edition we will discuss initial assessment and options for managing these types of wounds in general. In the next edition, we will discuss management of specific types of wounds and complications of wound healing.

Managing deeper wounds

Horse wounds can be managed in three different ways – primary closure, delayed primary closure or second intention healing.

Primary closure involves closing the exposed tissues and skin with sutures or staples soon after injury. For this to be successful, the wound needs to be minimally contaminated, fairly fresh with adequate blood supply to the skin and minimal tension on the skin edges. Primary closure results in the best cosmetic outcome and fastest healing time so is always preferable where possible.

Delayed primary closure is for managing heavily contaminated or infected wounds that need to be debrided and cleaned over several days, before the tissue is healthy enough to be sutured closed.

This type of wound management is usually most useful in areas where loose skin can be mobilised to allow closure without excessive tension. Wounds on the lower limbs are not generally good candidates for this as the skin retracts and primary closure is difficult to obtain after a few days.

Second intention healing is when a wound is left open to heal. This type of wound management is necessary when the wound edges cannot be closed due to loss of tissue or skin, if the wound is very infected or when the wound is in an area of excessive movement.

Examples of these types of wounds are those over the shoulder or rump where there is muscle exposed. Healing by second intention generally results in the least favourable cosmetic result and slowest return to function.

First Aid

When you find your horse with a wound of this nature, the first thing that needs to be decided is how you are going to manage the wound and it is best to consult your veterinarian.

While waiting for the veterinarian to arrive you can provide some first aid for your horse.

If there is a lot of bleeding and it is safe to do so, apply pressure or place a pressure bandage directly over the area until the veterinarian arrives. Be aware that leaving a tight bandage on for too long can lead to other problems associated with lack of blood supply.

If it is going to be some time before the veterinarian can attend, the wound can be covered to prevent any further contamination from debris or insects. A simple dressing such as gauze or even a sanitary pad held in place with Elastoplast or an exercise bandage can suffice.

If the wound is heavily contaminated it may help to gently hose the wound first to clean as much of the debris as possible before the veterinarian arrives. It is best to hold off on any topical antiseptic ointment or sprays at this stage.

> *"If there is a lot of bleeding and it is safe to do so, apply pressure or place a pressure bandage directly over the area until the veterinarian arrives*

Wound management

Assessment: The first step is to have a veterinarian assess the extent of the wound.

This usually needs to be done under sedation to enable a complete and safe examination. This is important in order to determine the depth of the wound, and whether there is a possibility that a synovial structure such as a joint or tendon sheath is involved. Wounds in the lower limb can involve lacerations of the tendons or bone exposure. Head wounds can be complicated by fractures and wounds on the abdomen and chest can penetrate into the body cavity. In these cases, referral to an equine hospital may be necessary for more intensive treatment.

A decision on whether the wound is closed primarily or left open to heal by second intention, is determined by the extent of tissue loss, the blood supply of the remaining tissues, the ability to bring the skin edges together with minimal tension and the degree of contamination.

Wound preparation and debridement

It is best to avoid topical antiseptics in the wound as they can damage the tissue. The veterinarian may infiltrate local anaesthetic into the edges of the wound in preparation of primary closure or debridement. Debridement is the process of removing foreign material, bacteria and devitalised or necrotic tissue from the wound and should be performed by a veterinarian.

With a well stocked First Aid Kit, and while you wait for the veterinarian to arrive you can provide some first aid for your horse.

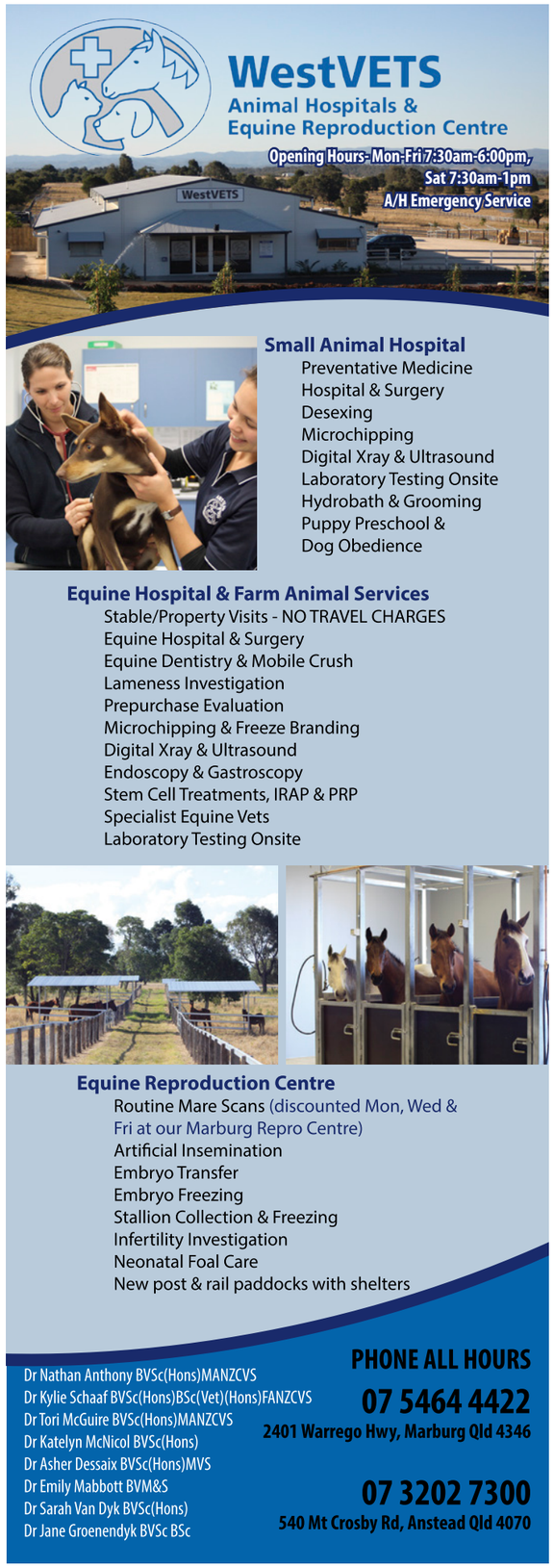

Wounds that are able to be bandaged should ideally be bandaged for as long as there is an open granulation bed. It has been shown that wound healing progresses more rapidly with better cosmetic end results when bandaging is used properly.

Horses' wounds are frequently heavily contaminated with dirt, plant material, timber and hair. Without adequate debridement, antibiotics and antiseptics will fail to effectively kill bacteria that reside in necrotic tissue. Excessive trauma to remaining tissue during debridement should be avoided as this will negatively affect wound healing.

Repair

Primary closure: In cases where primary closure is attempted the wound margins need to be apposed with minimal tension. Excessive tension on the primary suture line results in vascular damage with suture failure. Tension relieving sutures are commonly used to facilitate skin apposition while minimising tension on the primary suture line. A properly applied firm bandage is also a very useful way to minimise dead space where serum and blood can accumulate. For some wounds - particularly those involving the heels or coronet band - a thick firm bandage can minimise movement in the area which helps the healing process.

Sutures are removed 14 to 21 days after surgery, and tension relieving sutures may be removed earlier. Skin staples are also commonly used for wound repair particularly on the head.

Second intention healing: When equine wounds are left open to heal, it can be tempting to remove any loose redundant tissue. Unless the tissue is not viable it is best to leave it in place and it can always be removed later on. Bandaging the wound should always be considered. It has been shown that wound healing progresses more rapidly with better cosmetic end results when bandaging is used properly.

The advantages of bandaging include minimising environmental and bacterial contamination, protection from flies that can transmit parasites and sarcoids and prevention of proud flesh. Higher temperatures and moisture from wound exudate are proven to be beneficial to wound healing. Generally most dressing changes occur every two to five days depending on the amount of exudate the wound is producing.

Bandaging and ongoing aftercare

Wounds that are able to be bandaged should ideally be bandaged for as long as there is an open granulation bed. A layered bandage applied with firm even pressure is most commonly used for wounds on the lower limbs. This comprises of a non-stick dressing applied directly to the wound, a layer of cotton wool or similar breathable padding, a light bandage or wrap to hold the cotton wool in place, and a layer of Elastoplast or similar elasticised adhesive bandaging material to hold the whole bandage in place.

WestVETS

In cases where primary closure is attempted the wound margins need to be apposed with minimal tension. Sutures are removed 14 to 21 days after surgery, and tension relieving sutures may be removed earlier.

Bandaging material that constricts after being placed should be used with care. It is also best for a bandage to breathe to prevent sweat build up, therefore placing masking tape or similar over the entire bandage should be avoided.

Medication

Systemic antibiotics are often indicated for severe wound infections or if the wound is in close proximity to a synovial structure.

Non-steroidal anti–inflammatory medication, usually phenylbutazone is commonly used and both tetanus antitoxin and toxoid are recommended. Caustic ointments or sprays should be avoided in the early stages of healing as they damage healthy granulation tissue. Ointments containing cortisone are also best avoided in the early stages as they inhibit healing.

Below: Before and after photos of a healing shoulder wound, by second intention. Courtesy of Catherine Crozier

> *Second intention healing is when a wound is left open to heal.*

It is always important to remember that management of the wound changes as healing occurs, and each case is different.

Next month we will discuss a variety of specific wound examples and their management so stay tuned!

ABOUT THE AUTHOR: Sarah Van Dyk BVSc (Hons) - Mixed Animal Veterinarian. Sarah worked at WestVETS as an after hours nurse in her last year of Vet studies at UQ. Upon graduation in 2009, Sarah worked in Armidale, New South Wales in mixed practice for some time before re-joining the team at WestVETS as a mixed animal veterinarian. Her special interests are small animal surgery, farm animal medicine and surgery and equine medicine and reproduction. She also enjoys being attending veterinarian at endurance rides and other equestrian events. In her spare time, enjoys snowsports, art, horseriding and long distance running.